

# MODERN ADJUNCTS AND TECHNOLOGIES IN MICROSURGERY: AN HISTORICAL AND EVIDENCE-BASED REVIEW

GEORGE F. PRATT, M.B.B.S., P.G.Dip.Surg.Anat., WARREN M. ROZEN, M.B.B.S., B.Med.Sc., P.G.Dip.Surg.Anat., Ph.D.,\* DANIEL CHUBB, M.B.B.S., B.Med.Sc., IAIN S. WHITAKER, B.A. (Hons), M.A. Cantab., M.B.B.Chir., M.R.C.S., Ph.D., DAMIEN GRINSELL, M.B.B.S., F.R.A.C.S., MARK W. ASHTON, M.B.B.S., M.D., F.R.A.C.S., and RAFAEL ACOSTA, M.D., E.B.O.P.R.A.S.

*Background:* While modern reconstructive surgery was revolutionized with the introduction of microsurgical techniques, microsurgery itself has seen the introduction of a range of technological aids and modern techniques aiming to improve dissection times, anastomotic times, and overall outcomes. These include improved preoperative planning, anastomotic aides, and earlier detection of complications with higher salvage rates. Despite the potential for substantial impact, many of these techniques have been evaluated in a limited fashion, and the evidence for each has not been universally explored. The purpose of this review was to establish and quantify the evidence for each technique. *Methods:* A search of relevant medical databases was performed to identify literature providing evidence for each technology. Levels of evidence were thus accumulated and applied to each technique. *Results:* There is a relative paucity of evidence for many of the more recent technologies described in the field of microsurgery, with no randomized controlled trials, and most studies in the field comprising case series only. Current evidence-based suggestions include the use of computed tomographic angiography (CTA) for the preoperative planning of perforator flaps, the intraoperative use of a mechanical anastomotic coupling aide (particularly the Unilink<sup>®</sup> coupler), and postoperative flap monitoring with strict protocols using clinical bedside monitoring and/or the implantable Doppler probe. *Conclusion:* Despite the breadth of technologies introduced into the field of microsurgery, there is substantial variation in the degree of evidence presented for each, suggesting the role for much future research, particularly from emerging technologies such as robotics and modern simulators. © 2010 Wiley-Liss, Inc. *Microsurgery* 30:657–666, 2010.

The introduction of microsurgical techniques heralded a new era of options for the reconstructive surgeon. Improved outcomes in oncologic and trauma surgery were facilitated through the increased range of donor sites and range of tissues able to be use in the reconstructive process. However, the last 20 years have seen significant refinements in these techniques, with the aim of further improvements in outcome. In particular, a trend away from use of muscle flaps has aimed to reduce donor site morbidity associated with these operations, further aided by the development of perforator-based fasciocutaneous free flaps. This surgery, while achieving this goal, introduced a new degree of complexity and increasingly arduous dissections. The anatomical variability and size of these vessels has led to longer operating times and a potential increase in morbidity associated with long anesthetic times. As such, technological aids to this surgery have aimed to improve dissection times, anastomotic times, and overall outcomes. Despite these aims, the evidence for such techniques has not universally been explored.

We present a review of the literature investigating various technological aides and adjuncts in microsurgery. A focus is made on technologies which improve preoperative

planning, make for faster, safer micro-anastomoses, and allow earlier, reliable detection of postoperative complications leading to higher salvage rates. The level of evidence for each technique is quantified and areas where evidence is deficient are offered as potential areas for future research.

## METHODS

A thorough review of Medline and PubMed databases was undertaken using keywords “preoperative planning microsurgery,” “CTA free flap,” “imaging microsurgery,” “anastomotic coupler,” “microsurgical clips,” “microsurgery robot,” “free flap monitoring,” “glue microsurgery,” “microsurgery training,” “head mounted microscope,” “virtual reality microsurgery.” Both English and non-English language papers were included in the review. For more established technologies (such as preoperative imaging and anastomotic couplers), only papers reporting series of cases or particularly interesting technologies were included. Case reports were excluded. Recent papers were referenced over historical papers, while for recent technologies such as robotics, and head-mounted microscopes, all reports were included including case reports.

Based on results of the above database searches evidence for each technology was assessed and graded based on the widely accepted Oxford University Centre for Evidence-Based Medicine criteria (see the freely available website, CEBM.net). This system attributes levels of evidence to the quality of clinical trials published in the literature; ranging from Level 1 which comprises a systematic review of well-matched randomized control trials, through

Jack Brockhoff Reconstructive Plastic Surgery Research Unit, Room E533, Department of Anatomy and Cell Biology, The University of Melbourne, Grattan St, Parkville, Victoria 3050, Australia

\*Correspondence to: Warren M Rozen, M.B.B.S., B.Med.Sc., P.G.Dip.Surg. Anat., Ph.D., Jack Brockhoff Reconstructive Plastic Surgery Research Unit, Room E533, Department of Anatomy and Cell Biology, The University of Melbourne, Grattan St, Parkville, Victoria 3050, Australia.  
E-mail: warrenrozen@hotmail.com

Received 26 January 2010; Accepted 13 May 2010

Published online 23 August 2010 in Wiley Online Library (wileyonlinelibrary.com). DOI 10.1002/micr.20809

to Level 5 which comprises only the expert opinion of an eminent individual in the field. The level of evidence for each technology was thus assigned a grade.

## RESULTS

The search yielded 3,865 results, with the most pertinent according to search criteria being selected for inclusion. Currently, evidence exists for the use of the following technologies: CTA for preoperative planning of complex microsurgical procedures, the use of an intraoperative mechanical anastomotic coupling aide to facilitate faster anastomoses, and use of clinical monitoring with or without an implantable Doppler monitoring probe for the early detection of postoperative complications. Nonetheless, other technologies such as MRA, stereotaxy, robotic surgery, virtual reality planning and training, on-table angiography, head mounted microscopes, orthogonal polarized light, and laser speckle imaging are all nascent technologies with very little reported data. The existing data, while not representing a high level of evidence, is encouraging for such technologies, and there is notably no negative evidence for these technologies. These technologies thus represent areas of future research in the field.

### Preoperative Planning

With increasing refinements in the vascular anatomy of free flaps, particularly with the increasing use of perforator flaps (vessels >0.8 mm in diameter) and with supermicrosurgery (vessels <0.8 mm in diameter), preoperative planning has been sought as a tool to improving outcomes. Such techniques have the potential to identify individual vessels, map their entire course and dimensions, identify variations in individual anatomy, and plan flap design.

Doppler ultrasound has been the mainstay of preoperative imaging since the advent of the free flap, with the handheld Doppler probe introduced into widespread use for perforator mapping in 1990.<sup>1</sup> The hand-held unidirectional Doppler probe is cheap, quick, easily applied by the surgeon, and can be used adjunctively with other imaging techniques. Despite its benefits, there is significant time associated with perforator mapping with the Doppler probe, and it has shown to have low accuracy and high interobserver variability compared to other techniques.<sup>1-4</sup> The use of two-dimensional color as an addition to Doppler ultrasound has been an improvement on unidirectional Doppler.<sup>2-6</sup> This technique has improved sensitivity and specificity for identifying perforators, and is highly accurate at differentiating between arteries and veins. The major limitation of ultrasound is the dependence on operator reporting, with angiographic techniques sought to minimize interobserver variability. Catheter angiography is an invasive technique, but has been shown to improve operative

**Table 1.** Modern Techniques for the Preoperative Imaging of Microvascular Free Flaps and their Reported Level of Evidence According to the Oxford Centre for Evidence Based Medicine (CEBM) Levels of Evidence

Preoperative imaging technique	CEBM level of evidence for efficacy of technique
Doppler probe	4
Duplex (Eco-color Doppler) ultrasound	4
Catheter angiography	4
Computed tomographic angiography (CTA)	2b
Magnetic resonance imaging (MRI)	4
Magnetic resonance angiography (MRA)	4
Image-Guided Stereotactic Navigation	4

safety, particularly for the lower limb donor site.<sup>7,8</sup> Newer, noninvasive imaging techniques have been able to eliminate the interobserver variability and long scanning times associated with ultrasound, without the need for the invasiveness of catheter angiography. These advanced imaging technologies include computed tomography angiography (CTA) and magnetic resonance angiography (MRA).

Of the advanced imaging techniques able to perform angiographic analysis without intraarterial injection, only CTA has been shown to improve operative outcomes when compared to other imaging techniques (see Table 1).<sup>9-13</sup> CTA has been used as a noninvasive and effective tool for mapping the vascular supply to various body regions, including the head and lower limb,<sup>14-18</sup> and when compared to Duplex ultrasound in the mapping of abdominal wall perforators, CTA has been similarly shown to be a useful and superior technique.<sup>6</sup> CTA has increasingly become considered as the gold standard in preoperative imaging for DIEP flaps.<sup>9-12,19-24</sup> It is readily available, is extremely fast, and has a low interobserver variability. A limitation of CTA is its association with radiation exposure, however studies of the radiation dosage have shown that the radiation dose is less than 5 mSV, which is considerably less than a standard abdominal CT scan.<sup>25</sup> Both cadaveric and clinical studies have assessed the accuracy of CTA, demonstrating a sensitivity and positive predictive value of well over 99%,<sup>22</sup> and outcome studies in matched cohort studies have shown an improvement in operating times, flap-related complications, and donor site morbidity.<sup>11-13</sup>

Magnetic resonance imaging (MRI), without intravenous contrast, has been attempted in the past but with inadequate results for perforator mapping.<sup>26</sup> More recent results have suggested that there may be an improved utility of this technique with protocol adjustments.<sup>27</sup> With the use of contrast for better vessel visualization, MRA has been sought in this role. There are no studies showing any improvement in outcomes with the use of MRI or MRA, however some studies have suggested a role for

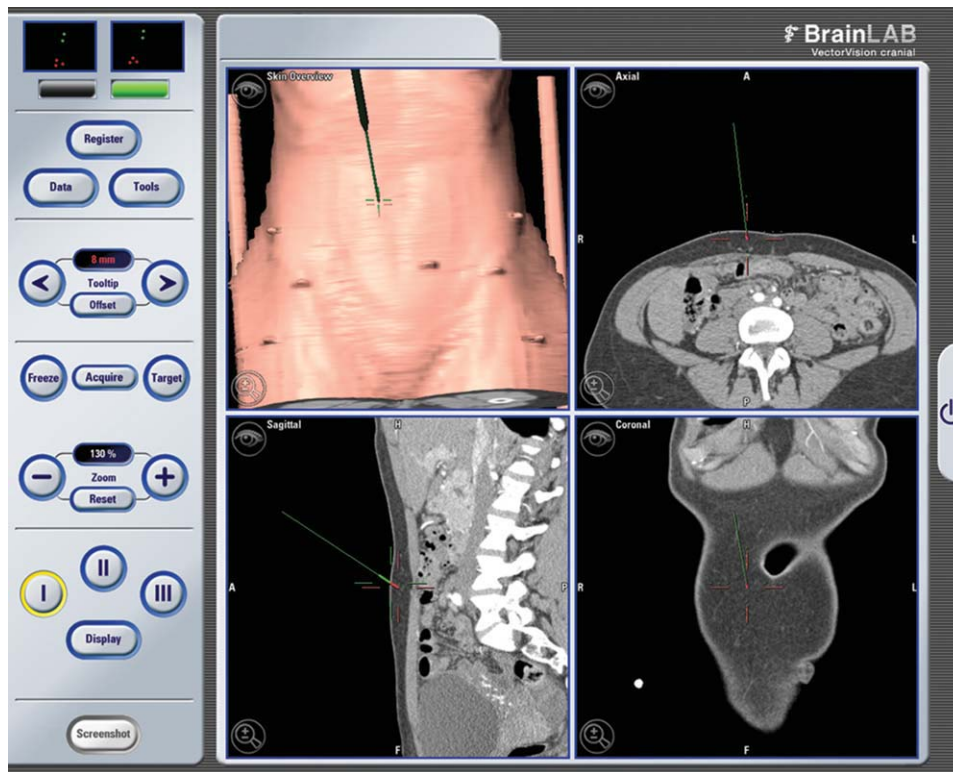

Figure 1. Stereotactic image-guided navigation of a computed tomography angiogram (CTA) of the abdominal wall vasculature, with three-dimensional reconstructed images shown on BrainLAB Vector Vision Cranial<sup>®</sup> software, demonstrating coronal, sagittal and axial planes of a localized deep inferior epigastric artery (DIEA) perforator. [Color figure can be viewed in the online issue, which is available at [wileyonlinelibrary.com](http://wileyonlinelibrary.com).]

MRA in perforator mapping,<sup>28–30</sup> while others have found no benefit over other modalities.<sup>31</sup> The main benefit of MRA is its lack of ionizing radiation, and while there is certainly less interobserver variability, expense and availability are limiting factors, as is the current resolution able to be achieved when compared to CTA.

A new technique, known as image-guided stereotactic navigation, can use preoperative scan data to map cutaneous vessels on a patient in real-time, both preoperatively and intraoperatively (see Fig. 1).<sup>21,32,33</sup> Demonstrated in a range of body regions, patients imaged with either CTA or MRA can undergo stereotactic mapping, providing a potentially improved accuracy to CTA or MRA alone. These techniques, although in their infancy, have the potential to guide surgical approach intraoperatively using “virtual surgery,” to minimize surgical morbidity. Newer techniques have the potential to map vasculature without the use of any imaging, with thermal cameras for example able to map vessels through the detection of thermal heat alone, although such devices have not yet reached reporting in the literature.

### Microanastomotic Aides

The last 20 years have seen the continued development of various devices designed to make surgical anas-

tomoses easier and achieve reliably higher patency rates. In addition to overall flap survival, improvements in flap design have been sought. While preoperative imaging has aided the selection of the optimal vessels in supply to the flap, intraoperative techniques for assessing flap perfusion have been developed.

The use of devices to replace traditional suturing have been developed, with Zdolsek et al. reporting a study of novice microsurgions performing microvascular anastomoses on rats using three different techniques—traditional hand suturing, the Unilink/3M<sup>®</sup> Microvascular Anastomotic Coupler, and the Vessel Closure System<sup>®</sup> (VCS) Clip applicator.<sup>34</sup> They showed a significant learning curve in terms of operative ease and speed in the suture group but no such steep learning curve in the other groups, prompting the conclusion that mechanical anastomotic techniques are easier to learn than traditional suturing. Despite their introduction into clinical practice many years ago, uptake of these technologies has been slow and sporadic with only a handful of sizeable series reported in the literature and limited evidence supporting their more widespread use (see Table 2).

Anastomotic couplers such as the Unilink/3M<sup>®</sup> Microvascular Anastomotic Coupler have been in use since the 1960s.<sup>35</sup> While originally thought to be suitable for

**Table 2.** Modern Techniques used Intra-Operatively During Microvascular Free Flaps and their Reported Level of Evidence According to the Oxford Centre for Evidence Based Medicine (CEBM) Levels of Evidence

Method	CEBM level of evidence for efficacy of technique
Unilink <sup>®</sup> anastomotic coupler	2b
VCS autosuture	2b
Nanitol <sup>®</sup> medtronic U clip	4
Fibrin glues	4
Cyanoacrylates	4
Leica <sup>®</sup> head mounted microscope	Nil
Robot (daVinci <sup>®</sup> )	4
Indocyanine green	4
Virtual reality training in microsurgery	Nil

venous anastomoses only, their use now includes arterial anastomoses.<sup>36–40</sup> Some series have also demonstrated the suitability of the coupler for use in end to side anastomoses.<sup>40,41</sup> Ring couplers have been shown to significantly reduce average anastomotic times and technical difficulty, effectively homogenizing results between senior and junior members of surgical teams,<sup>34,36–39</sup> and patency rates are generally reported as equal or superior to traditionally sutured anastomoses.<sup>36–39</sup> These studies have included well-matched controlled trials, achieving level 2b evidence. Early reports questioned outcomes from ring couplers in irradiated fields, however more recent clinical,<sup>42</sup> and animal,<sup>41</sup> studies support its use in this setting.

Autosuture<sup>™</sup> Titanium Vessel Closure System<sup>®</sup> (VCS) clips were developed in 1995 as a nonpenetrating microvascular anastomotic tool. The applicator places titanium clips onto everted anastomotic cuffs, resulting in the absence of intraluminal foreign material. The VCS<sup>®</sup> clip applicator has been used for both end-to-end and end-to-side anastomoses.<sup>43–47</sup> Various series have demonstrated that the VCS<sup>®</sup> clip applicator is easy to use and faster than traditional sutured anastomoses.<sup>38,43–45</sup> In addition, patency rates have been shown to be equal and histological evidence of endothelial healing has been demonstrably swifter in clipped anastomoses. Although some early small series such as Yamamoto et al.<sup>48</sup> reported good patency rates, much of the data in the literature regarding clipped anastomoses results from the work of Zeebregts including several review articles.<sup>38,46,47</sup> Another large series has been published by Cope et al.<sup>44</sup>

There has been an increasing use of adhesives in surgery in recent times. There are two main groups of surgical adhesives: cyanoacrylates and thrombin-based “fibrin glues.” Cyanoacrylate glues have been used in surgery for many years, particularly in minor sutureless skin surgery (e.g., hystoacryl<sup>®</sup>, Dermabond<sup>®</sup>). Various other uses have been reported in the literature, including roles in microvascular reconstructive surgery. More recently,

fibrin glues (e.g., Tisseel<sup>®</sup>, Tissucol<sup>®</sup>) and thrombin-containing hemostatic products (e.g., Floseal<sup>®</sup>) have been investigated for potential roles. While these substances each contain thrombin, Floseal relies on the presence of endogenous fibrinogen from the bleeding surgical field for activation, whereas Tisseel<sup>®</sup> is a two-part glue containing thrombin and fibrinogen. While these newer generation thrombin-based adhesives have potential roles in microsurgery, there has always been concern about the risk of inciting occlusive thrombosis in microvascular anastomoses. One large series ( $n = 349$ ) demonstrated the use of Tisseel<sup>®</sup> as a pedicle stabilizing agent to facilitate microanastomosis during DIEP flap breast reconstruction.<sup>49</sup> This study suggested no increase in rates of anastomotic thrombotic complications, however benefits were poorly quantified. Other series confirm the safety of such techniques.<sup>50–52</sup>

Recently another clipping system has become available—the Medtronic<sup>®</sup> U-Clip<sup>®</sup>. This combines suturing with a clip, using a needle and thread with a clipping mechanism instead of the need to tie knots. There has been some limited reporting of this clipping system in coronary artery bypass surgery but very little in reconstructive microsurgery. A case report,<sup>53</sup> and a series of three cases have reported generally rapid anastomoses with a reduced learning curve over other mechanical anastomotic aides.<sup>54</sup>

## Robotics

The use of robots in surgery has become an area of popular interest, with wide use in urology and cardiac surgery. The robot allows human factors such as hand tremor to be eliminated from the surgical process, potentiating safer, reproducible results—although these have yet to be convincingly demonstrated. To date, to our knowledge only two reports of the use of robots (the da Vinci Surgical System<sup>®</sup>) in performing microsurgery exists. Katz et al. successfully used the system to perform a free flap in a pig in 2005, and while demonstrating feasibility, they concluded that the applications were limited pending the development of true microsurgical instruments for the robot.<sup>55</sup> The following year Karamanoukian et al.<sup>56</sup> demonstrated the feasibility of robotic assisted anastomoses in a series in piglets. While not microsurgery *per se*, the robot has been shown to be useful in dissection of internal mammary arteries both for use as cardiac conduits and as recipient vessels in reconstructive breast surgery.<sup>57</sup> Robotics in surgery has evolved fast in other areas of surgery and we identify this area as one needing further research in the field of microsurgery.

## Leica<sup>®</sup> Head Mounted Microscope

The Leica<sup>®</sup> Headmounted microscope HM500 (formerly the Varioscope<sup>®</sup> M5) is a head mounted personal



microscope introduced by Leica<sup>®</sup> capable of magnifications in the range of 2× to 9×. The HM500<sup>®</sup> has been used for various procedures requiring magnification including free flap reconstructions by a single unit in Italy<sup>58,59</sup> and neurosurgery.<sup>60</sup> It may be of considerable use in the future allowing unrestricted movement of the surgeon, more options for operating position, and possibly expanding the scope of microsurgery to nontertiary institutions.

### Training Simulators

The role of training models and simulators has been established and well vindicated in other surgical specialties such as laparoscopic general surgery. Traditionally, in microsurgery, training has taken the form of performing anastomoses on rats in animal laboratories. However, increasing refinements in computer simulations and the ever mounting pressure to reduce the use of animal testing in science has led to development of various training modules for microsurgical skills in neurosurgery,<sup>61</sup> ophthalmology,<sup>62</sup> and reconstructive surgery.<sup>63</sup> These simulators are yet to be adopted universally but may well represent the future of skills development in microsurgery. Systems such as the Dextroscope<sup>®</sup> Volumetric Interactive 3D system which incorporates MRI or CT data into a computer-generated virtual reality model, allowing the surgeon to train for an operation taking into account the anatomical data of a specific patient. This system has been used in neurosurgery, and other virtual reality simulators currently in use include the EyeSi<sup>®</sup> Ophthalmological simulator, but its application to nonophthalmic microsurgery is unclear.

### Intraoperative Assessment of Flap Perfusion

The ability to assess flap perfusion intraoperatively has long been a topic of interest, with flap design able to be modified based on such findings, and partial flap necrosis rates minimized. Traditionally, clinical assessment of the flap periphery has been the mainstay of such assessment, and has formed the basis for evaluating the flap zones to be excised (such as the excision of the distal “zone 4” in a transverse rectus abdominis myocutaneous (TRAM) flap). Sequential clamping of pedicles prior to division has also been used to ensure total perfusion of the flap on selected perforators. Historically, techniques such as direct measurement of flap perfusion pressure and real-time X-ray angiography have been used to confirm and quantify the perfusion of free flaps intraoperatively. While these have been useful, they are often invasive or associated with inaccuracies. A new technique for assessing the on-table perfusion of free flaps has emerged in recent time: near infrared angiography with indocyanine green dye. Indocyanine green absorbs light in the near infrared spectrum and emits fluorescence at a wavelength

which penetrates human tissues (~835 nm). After injection, this fluorescence is recorded to provide information regarding the perfusion of a given area of tissue. This technique has gained popularity as a tool for assessing the on-table perfusion of a flap once raised on a given vessel and for determining which zones of a flap should be removed to ensure reliable perfusion to the periphery.<sup>64–66</sup> Recent studies with the technique have shown that by using this technique, perfusion can be shown to be different between individuals, and that in-vivo assessment may be different to long-held anatomical concepts; indeed, the Hartrampf zones of perfusion in TRAM flaps were shown to likely not be correct and should be reconsidered to be zones I and II ipsilateral and zones III and IV contralateral.<sup>67</sup> In addition, the technique has potential uses for assessing the perfusion of a free flap following microanastomoses and as a postoperative flap monitoring tool. Despite the promise of this technique as a valuable aide to flap design and monitoring, as well as to developing an overall understanding of perforator flap territories, the current level of evidence is restricted to small case series.

### Early Detection of Postoperative Complications

Success rates for free tissue transfer have increased steadily and significantly since their introduction in the 1970s. Nonetheless, abrupt circulatory failure resulting in compromised tissue perfusion and flap necrosis continues to occur at a rate of ~5–20%.<sup>68,69</sup> Any attempt at salvage requires urgent surgical reexploration to restore circulation and thus oxygen and nutrient supply to the flap. As flap salvage rates appear to be inversely proportional to the time delay between occlusion of vessels and reexploration,<sup>68,70–73</sup> methods of accurate and early detection of circulatory compromise are desirable. Over the last two decades many devices and techniques have been described in an effort to provide reliable early detection of compromised flaps. Indeed, the sheer volume of different monitoring techniques and the absence of any consensus apart from the use of basic clinical monitoring<sup>74–76</sup> suggest that none is absolutely reliable.

As discussed by Creech and Miller,<sup>77</sup> the ideal monitoring solution needs to be easy to interpret, reliable, and afford early detection of vascular compromise allowing less experienced or junior members of staff to safely look after free flaps in the post operative period with no ambiguity or subjectivity. In addition, the system would ideally detect flap threatening circulatory problems prior to closure during the primary surgery.<sup>78</sup>

Flap monitoring has traditionally been performed with the use of clinical parameters such as surface temperature, color, capillary refill, and tactility. Handheld Doppler monitoring of the anastomosis has been in use almost since the inception of the free flap, and is close to ubiqu-

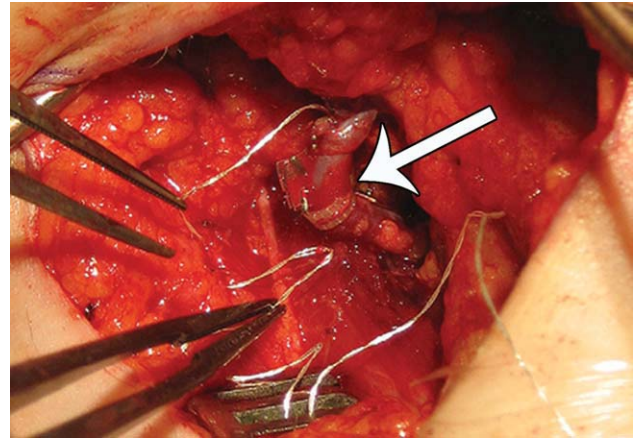
**Table 3.** Modern Techniques for the Postoperative Monitoring of Microvascular Free Flaps and their Reported Level of Evidence According to the Oxford Centre for Evidence Based Medicine (CEBM) Levels of Evidence

Postoperative monitoring technique	CEBM level of evidence for efficacy of technique
Surface temperature	4
Implanted temperature	4
Fluometry	2b
pH	4
pO <sub>2</sub> /NIRS	4
Implanted pO <sub>2</sub>	4
PPG	4
Laser doppler	2b
Handheld doppler	Nil
Contrast ultrasound	5
Implanted Doppler ultrasound (Cook-Swartz probe)	2a
Microdialysis	4
Impedance plethysmography	5
Confocal microscopy	4
Nuclear medicine	5

uitous in microsurgical units in the UK.<sup>74–76</sup> These techniques have met with moderate success in units which employ these processes rigorously, with large series reporting up to 80% salvage rates of compromised flaps.<sup>69</sup> While clinical monitoring is still the mainstay in the postoperative care of free flaps, new techniques to monitor flaps in an attempt to improve flap salvage rates have been developed. Given the disastrous consequences for a patient in the setting of even a single flap failure, significant research into new devices has been undertaken (see Table 3).

Recent techniques reported for postoperative monitoring include pulse oximetry,<sup>79–91</sup> perfusion photoplethysmography,<sup>92,93</sup> surface temperature measurement,<sup>94,95</sup> fluorometry,<sup>95–102</sup> microdialysis,<sup>103–106</sup> ultrasound,<sup>79,107–109</sup> implanted (Cook-Swartz) Doppler probes (see Fig. 2),<sup>110–119</sup> laser Doppler flowmetry,<sup>120–126</sup> impedance plethysmography,<sup>127–129</sup> confocal microscopy,<sup>130</sup> nuclear medicine,<sup>131–133</sup> subcutaneous pH measurement,<sup>95,134–136</sup> hydrogen clearance,<sup>137,138</sup> externalization of part of a buried flap,<sup>122,139</sup> and white light spectrometry.<sup>123</sup>

One of the main problems with research involving monitoring techniques is the difficulty in objectively assessing the usefulness of a monitoring technique. Most articles written about monitoring techniques are noncomparative case series which do not allow for objective assessment of the success or otherwise of the particular technique being discussed. As the main objective of any monitoring technique is to allow for a greater rate of flap salvage, the most obvious measure of monitoring success is whether the use of that particular method can improve the flap salvage rate. Secondary measures include ease of



**Figure 2.** Application of the Cook-Swartz implantable Doppler probe, demonstrating a silicone cuff (arrow) distal to the venous anastomosis, with microclips used to secure the cuff around the vessel adventitia. Image reproduced with permission from: Rozen WM, Enajat M, Whitaker IS, Smit JM, Audolfsson T, Acosta R. Postoperative monitoring of lower limb free flaps with the Cook-Swartz implantable doppler probe: A clinical trial. *Microsurgery*. 2009 Dec 4; [Epub ahead of print]. [Color figure can be viewed in the online issue, which is available at [wileyonlinelibrary.com](http://wileyonlinelibrary.com).]

use and the false positive rate, a measure which is important as it reduces the rate of needless return to theater if a monitoring technique is heavily relied upon. To date only quantitative fluorometry, the implanted Doppler probe, and laser Doppler flowmetry have demonstrated the ability to improve flap salvage rates.<sup>102,116,126,140</sup>

Most of the techniques named above are still the subjects of further research in microsurgery, and it remains possible that any one of these techniques could in future become a mainstay of flap monitoring. There are also some new techniques that may be able to directly visualize the flap vasculature in an attempt to more accurately determine the causes of flap compromise. These techniques include, but are not limited to, laser speckle imaging and orthogonal polarized light<sup>141–144</sup> The concept of being able to directly visualize flap microcirculation could be an exciting addition to microsurgery in years to come.

## DISCUSSION

The last 20 years has seen a period of consistent evolution and amelioration of microsurgical techniques. Many surgeons have used available technologies in novel ways, or undertaken learning curves to become proficient with new technologies. Despite the advent of such technologies, the benefits of many of these have remained poorly quantified and their uptake often remained very institution specific. While there are no multicenter randomized control trials to support any of the innovations described, there is a wealth of published data series

to support some of the benefits, and to demonstrate safety in most cases.

The potential benefits of many of these techniques include: more accurate preoperative planning, quicker and easier micro-anastomoses, and the reliable early detection of postoperative complications resulting in higher salvage rates of compromised flaps. These benefits can result in tangible improvements in outcome: shorter operative times, reduced operative complications, and improved flap survival rates. While the evidence for some of these techniques is not universally high, the evidence presented can provide reasonable suggestions regarding current gold standards. Current evidence-based suggestions include the use of CTA for the preoperative planning of perforator flaps, the intraoperative use of a mechanical anastomotic coupling aide (particularly the Unilink(anastomotic coupler), and postoperative flap monitoring with strict protocols using clinical bedside monitoring and/or the implantable Doppler probe.

## CONCLUSION

With much of this research published within the last 12 months, it is evident that research in this field is ongoing, and that such research will greatly enhance the uptake of these technologies. Specifically, the need for high quality multicenter randomized control trials is identified, and the need for international consensus meetings (such as the “Navarra” meeting for preoperative imaging in 2008),<sup>145</sup> will promote open discussion and allow surgeons to shape the future of microsurgery.

## REFERENCES

1. Taylor GI, Doyle M, McCarten G. The Doppler probe for planning flaps: Anatomical study and clinical applications. *Br J Plast Surg* 1990;43:1–16.
2. Blondeel PN, Beyens G, Vergaeghe R, Van Landuyt K, Tonnard P, Monstrey SJ, Matton G. Doppler flowmetry in the planning of perforator flaps. *Br J Plast Surg* 1998;51:202–209.
3. Giunta RE, Geisweid A, Feller AM. The value of preoperative Doppler sonography for planning free perforator flaps. *Plast Reconstr Surg* 2000;105:2381–2386.
4. Hallock GG. Doppler sonography and colour duplex imaging for planning a perforator flap. *Clin Plast Surg* 2003;30:347–357.
5. Hallock GG. Evaluation of fasciocutaneous perforators using color duplex imaging. *Plast Reconstr Surg* 1994;94:644–651.
6. Rozen WM, Phillips TJ, Ashton MW, Stella DL, Gibson RN, Taylor GI. Preoperative imaging for DIEA perforator flaps: A comparative study of computed tomographic angiography and doppler ultrasound. *Plast Reconstr Surg* 2008;121:9–16.
7. May JWJ, Athanasoulis CA, Donelan MB. Preoperative magnification angiography of donor and recipient sites for clinical free transfer of flaps or digits. *Plast Reconstr Surg* 1979;64:483–490.
8. Young DM, Trabulsky PP, Anthony JP. The need for preoperative leg angiography in fibula free flaps. *J Reconstr Microsurg* 1994;10:283–287.
9. Alonso-Burgos A, Garcia-Tutor E, Bastarrika G, Cano D, Martinez-Cuesta A, Pina LJ. Preoperative planning of deep inferior epigastric artery perforator flap reconstruction with multi-slice-CT angiography: Imaging findings and initial experience. *J Plast Reconstr Aesthet Surg* 2006;59:585–593.
10. Masia J, Clavero JA, Larranaga JR, Alomar X, Pons G, Serret P. Multidetector-row computed tomography in the planning of abdominal perforator flaps. *J Plast Reconstr Aesthet Surg* 2006;59:594–599.
11. Rozen WM, Anavekar NS, Ashton MW, Stella DL, Grinsell D, Bloom RJ, Taylor GI. Does the preoperative imaging of perforators with CT angiography improve operative outcomes in breast reconstruction? *Microsurgery* 2008;28:516–523.
12. Smit JM, Dimopoulou A, Liss AG, Zeebregts CJ, Kildal M, Whitaker IS, Magnusson A, Acosta R. Preoperative CT angiography reduces surgery time in perforator flap reconstruction. *J Plast Reconstr Aesthet Surg* 2009;62:551.
13. Uppal RS, Casaer B, Van Landuyt K, Blondeel P. The efficacy of preoperative mapping of perforators in reducing operative times and complications in perforator flap breast reconstruction. *J Plast Reconstr Aesthet Surg* 2009;62:859–864.
14. Bluemke DA, Chambers TP. Spiral CT angiography: An alternative to conventional angiography. *Radiology* 1995;195:317–319.
15. Chow LC, Napoli A, Klein MB, Chang J, Rubin GD. Vascular mapping of the leg with multi-detector row CT angiography prior to free-flap transplantation. *Radiology* 2005;237:353–360.
16. Karanas YL, Antony A, Rubin G, Chang J. Preoperative CT angiography for free fibula transfer. *Microsurgery* 2004;24:125–127.
17. Nagler RM, Braun J, Daitzman M, Laufer D. Spiral CT angiography: An alternative vascular evaluation technique for head and neck microvascular reconstruction. *Plast Reconstr Surg* 1997;100:1697–1702.
18. Rieker O, Duber C, Schmiedt W, Von Zitzewitz H, Schweden F, Thelen M. Prospective comparison of CT angiography of the legs with intraarterial digital subtraction angiography. *Am J Roentgenol* 1996;166:269–276.
19. Phillips TJ, Stella DL, Rozen WM, Ashton MW, Taylor GI. Abdominal wall CT angiography: A detailed account of a newly established preoperative imaging technique. *Radiology* 2008;249:32–44.
20. Rosson GD, Williams CG, Fishman EK, Singh NK. 3D CT angiography of abdominal wall vascular perforators to plan DIEAP flaps. *Microsurgery* 2007;27:641–646.
21. Rozen WM, Ashton MW, Ferris S, White DC, Phillips TJ, Taylor GI. Developments in perforator imaging for the anterolateral thigh flap: CT angiography and CT-guided stereotaxy. *Microsurgery* 2008;28:227–232.
22. Rozen WM, Ashton MW, Stella DL, Phillips TJ, Grinsell D, Taylor GI. The accuracy of CT angiography for mapping the perforators of the DIEA: A blinded, prospective cohort study. *Plast Reconstr Surg* 2008;122:1003–1009.
23. Tregaskiss AP, Goodwin AN, Bright LD, Ziegler CH, Acland RD. Three-dimensional CT angiography: A new technique for imaging microvascular anatomy. *Clin Anat* 2007;20:116–123.
24. Masia J, Larranaga JR, Clavero JA, Vives L, Pons G, Pons JM. The value of the multidetector row computed tomography for the preoperative planning of deep inferior epigastric artery perforator flap. *Ann Plast Surg* 2008;60:29–36.
25. Rozen W, Whitaker I, Stella D, Phillips T, Einsiedel P, Acosta R, Ashton M. The radiation exposure of computed tomographic angiography (CTA) in DIEP flap planning: Low dose but high impact. *J Plast Reconstr Aesthet Surg* 2009;62:e654–e655.
26. Ahn CY, Narayanan K, Shaw WW. In vivo anatomic study of cutaneous perforators in free flaps using magnetic resonance imaging. *J Reconstr Microsurg* 1994;10:157–163.
27. Masia J, Kosutic D, Cervelli D, Clavero JA, Monill JM, Pons G. In search of the ideal method in perforator mapping: Noncontrast magnetic resonance imaging. *J Reconstr Microsurg* 2010;26:29–35.
28. Alonso-Burgos A, Garcia-Tutor E. Clinical experience in MR angiography in DIEP and perforator flaps. In: 2nd International Course on Planning DIEP and Perforator Flaps with 3D Angio-CT and Angio-MR. Pamplona, Navarra, Spain: Abstract Program; 2008.
29. Alonso-Burgos A, Garcia-Tutor E, Bastarrika G, Benito A, Domínguez PD, Zubieta JL. Preoperative planning of DIEP and SGAP flaps: Preliminary experience with magnetic resonance angiography



- using 3-tesla equipment and blood-pool contrast medium. *J Plast Reconstr Aesthet Surg* 2010;63:298–304.
30. Neil-Dwyer JG, Ludman CN, Schaverein M, McCulley SJ, Perks AG. Magnetic resonance angiography in preoperative planning of deep inferior artery perforator flaps. *J Plast Reconstr Aesthet Surg* 2009;62:1661–1665.
  31. Rozen WM, Stella DL, Bowden J, Taylor GI, Ashton MW. Advances in the preoperative planning of DIEA perforator flaps: Magnetic resonance angiography. *Microsurgery* 2009;29:119–123.
  32. Rozen WM, Ashton MW, Stella DL, Phillips TJ, Taylor GI. Stereotactic image-guided navigation in the preoperative imaging of perforators for DIEP flap breast reconstruction. *Microsurgery* 2008;28:417–423.
  33. Rozen WM, Buckland A, Ashton MW, Stella DL, Phillips TJ, Taylor GI. Image-guided, stereotactic perforator flap surgery: A prospective comparison of current techniques and review of the literature. *Surg Radiol Anat* 2009;31:401–408.
  34. Zdolsek J, Ledin H, Lidman D. Are mechanical microvascular anastomoses easier to learn than suture anastomoses? *Microsurgery* 2005;25:596–598.
  35. Nakayama K, Tamiya T, Yamamoto K, Akimoto S. A simple new apparatus for small vessel anastomosis (free autograft of the sigmoid included). *Surgery* 1962;52:918–931.
  36. Ahn CY, Shaw WW, Berns S, Markowitz BL. Clinical experience with the 3M microvascular coupling anastomotic device in 100 free-tissue transfers. *Plast Reconstr Surg* 1994;93:1481–1484.
  37. Spector JA, Draper LB, Levine JP, Ahn CY. Routine use of microvascular coupling device for arterial anastomosis in breast reconstruction. *Ann Plast Surg* 2006;56:365–368.
  38. Zeebregts C, Acosta R, Bölander L, van Schilfgaarde R, Jakobsson O. Clinical experience with non-penetrating vascular clips in free-flap reconstructions. *Br J Plast Surg* 2002;55:105–110.
  39. Chernichenko N, Ross DA, Shin J, Chow JY, Sasaki CT, Ariyan S. Arterial coupling for microvascular free tissue transfer. *Otolaryngol Head Neck Surg* 2008;138:614–618.
  40. Ragnarsson R, Berggren A, Ostrup LT, Gilbert RW. Arterial end-to-side anastomosis with the UNILINK system. *Ann Plast Surg* 1989;22:405–415.
  41. Ragnarsson R, Berggren A, Ostrup LT. Microvenous end-to-side anastomosis: An experimental study comparing the Unilink system and sutures. *J Reconstr Microsurg* 1989;5:217–224.
  42. Ross DA, Chow JY, Shin J, Restifo R, Joe JK, Sasaki CT, Ariyan S. Arterial coupling for microvascular free tissue transfer in head and neck reconstruction. *Arch Otolaryngol Head Neck Surg* 2005;131:891–895.
  43. Cariou JL, Lambert F, Bey E, Bellavoire A. Mechanical vascular clips with an automatic stapler in reconstructive microsurgery. Apropos of 16 clinical cases. *Chirurgie* 1997;122:511–514.
  44. Cope C, Lee K, Stern H, Pennington D. Use of the vascular closure staple clip applier for microvascular anastomosis in free-flap surgery. *Plast Reconstr Surg* 2000;106:107–110.
  45. De Lorenzi F, van der Hulst RRWJ, Boeckx WD. VCS auto suture stapled microvascular anastomoses in lower leg free flaps. *Plast Reconstr Surg* 2002;109:2023–2030.
  46. Zeebregts CJ, Kirsch WM, Reijnen MMPJ, Zhu YH, van den Dungen JJAM. Expanding use of nonpenetrating clips in various surgical specialties. *Surg Technol Int* 2005;14:85–95.
  47. Zeebregts CJ, Kirsch WM, van den Dungen JJ, Zhu YH, van Schilfgaarde R. Five years' world experience with nonpenetrating clips for vascular anastomoses. *Am J Surg* 2004;187:751–760.
  48. Yamamoto N, Nakai H, Satoh Y, Oshima Y. Clinical application of a nonpenetrating microvascular stapling device for vascularized free tissue transfer. *Ann Plast Surg* 1999;42:49–55.
  49. Andree C, Munder BJJ, Behrendt P, Hellmann S, Audretsch W, Voigt M, Reis C, Beckmann M, Horch R, Bach A. Improved safety of autologous breast reconstruction surgery by stabilisation of microsurgical vessel anastomoses using fibrin sealant in 349 free DIEP or fascia-muscle-sparing (fms)-TRAM flaps: A two-centre study. *Breast (Edinburgh Scotland)* 2008;17:492–498.
  50. Schwabegger AH, Engelhardt TO, Jeschke J. Stabilization of microvascular pedicles in intricate locations using fibrin glue. *Microsurgery* 2008;28:509–513; discussion 14–15.
  51. Cho AB, Wei TH, Torres LR, Júnior RM, Rugiero GM, Aita MA. Fibrin glue application in microvascular anastomosis: Comparative study of two free flaps series. *Microsurgery* 2009;29:24–28.
  52. Cho AB, Júnior RM. Application of fibrin glue in microvascular anastomoses: Comparative analysis with the conventional suture technique using a free flap model. *Microsurgery* 2008;28:367–374.
  53. Taylor J, Katz R, Singh N. Use of the U-clip for microvascular anastomosis. *Microsurgery* 2006;26:550–551.
  54. Baynosa RC, Stutman R, Mahabir RC, Zamboni WA, Khiabani KT. Use of a novel penetrating, sutureless anastomotic device in arterial microvascular anastomoses. *J Reconstr Microsurg* 2008;24:39–42.
  55. Katz RD, Rosson GD, Taylor JA, Singh NK. Robotics in microsurgery: Use of a surgical robot to perform a free flap in a pig. *Microsurgery* 2005;25:566–569.
  56. Karamanoukian RL, Finley DS, Evans GRD, Karamanoukian HL. Feasibility of robotic-assisted microvascular anastomoses in plastic surgery. *J Reconstr Microsurg* 2006;22:429–431.
  57. Boyd B, Umansky J, Samson M, Body D, Stahl K. Robotic harvest of internal mammary vessels in breast reconstruction. *J Reconstr Microsurg* 2006;22:261–266.
  58. Chiummariello S, Fioramonti P, Menichini G, Scuderi N, Alfano C. A new type of magnification system in free microvascular tissue transfer: Varioscope M5. *Microsurgery* 2007;27:533–535.
  59. Chiummariello S, Monarca C, Andrea Dessy L, Alfano C, Scuderi N. Varioscope M5: A new type of magnification system in anterolateral thigh perforator free-flap surgery. *J Reconstr Microsurg* 2009;25:227–231.
  60. Kuchta J, Simons P. Spinal neurosurgery with the head-mounted “Varioscope” microscope. *Cen Eur Neurosurg* 2009;70:98–100.
  61. Wong GKC, Zhu CXL, Ahuja AT, Poon WS. Stereoscopic virtual reality simulation for microsurgical excision of cerebral arteriovenous malformation: Case illustrations. *Surg Neurol* 2009;72:69–72.
  62. Solverson DJ, Mazzoli RA, Raymond WR, Nelson ML, Hansen EA, Torres MF, Bhandari A, Hartranft CD. Virtual reality simulation in acquiring and differentiating basic ophthalmic microsurgical skills. *Simul Healthc* 2009;4:98–103.
  63. Erel E, Aiyenibe B, Butler PEM. Microsurgery simulators in virtual reality: Review. *Microsurgery* 2003;23:147–152.
  64. Giunta RE, Holzbach T, Taskov C, Holm PS, Brill T, Busch R, Gansbacher B, Biemer E. Prediction of flap necrosis with laser induced indocyanine green fluorescence in a rat model. *Br J Plast Surg* 2005;58:695–701.
  65. Holm C, Dornseifer U, Sturtz G, Basso G, Schuster T, Ninkovic M. The intrinsic transit time of free microvascular flaps: Clinical and prognostic implications. *Microsurgery* 2010;30:91–96.
  66. Holm C, Mayr M, Hofter E, Becker A, Pfeiffer UJ, Muhlbauer W. Intraoperative evaluation of skin-flap viability using laser-induced fluorescence of indocyanine green. *Br J Plast Surg* 2002;55:635–644.
  67. Holm C, Mayr M, Hofter E, Ninkovic M. Perfusion zones of the DIEP flap revisited—A clinical study. *Plast Reconstr Surg* 2006;117:37–43.
  68. Bui DT, Cordeiro PG, Hu QY, Disa JJ, Pusic A, Mehrara BJ. Free flap reexploration: Indications, treatment, and outcomes in 1193 free flaps. *Plast Reconstr Surg* 2007;119:2092–2100.
  69. Disa JJ, Cordeiro PG, Hidalgo DA. Efficacy of conventional monitoring techniques in free tissue transfer: An 11-year experience in 750 consecutive cases. *Plast Reconstr Surg* 1999;104:97–101.
  70. Smit JM, Acosta R, Zeebregts CJ, Liss AG, Anniko M, Hartman EH. Early reintervention of compromised free flaps improves success rate. *Microsurgery* 2007;27:612–616.
  71. Smit JM, Zeebregts CJ, Acosta R. Timing of presentation of the first signs of vascular compromise dictates the salvage outcome of free flap transfers. *Plast Reconstr Surg* 2008;122:991–992.
  72. Hofer SO, Damen TH, Mureau MA, Rakhorst HA, Roche NA. A critical review of perioperative complications in 175 free deep inferior epigastric perforator flap breast reconstructions. *Ann Plast Surg* 2007;59:137–142.
  73. Chen K-T, Mardini S, Chuang DC-C, Lin C-H, Cheng M-H, Lin Y-T, Huang W-C, Tsao C-K, Wei F-C. Timing of presentation of the first signs of vascular compromise dictates the salvage out-



- come of free flap transfers. *Plast Reconstr Surg* 2007;120:187–195.
74. Whitaker IS, Karoo ROS, Oliver DW, Ganchi PA, Gulati V, Malata CM. Current techniques in the post-operative monitoring of microvascular free-tissue transfers. *Eur J Plast Surg* 2005;27:315–321.
  75. Whitaker IS, Gulati V, Ross GL, Menon A, Ong TK. Variations in the postoperative management of free tissue transfers to the head and neck in the United Kingdom. *Br J Oral Maxillofac Surg* 2007;45:16–18.
  76. Whitaker IS, Oliver DW, Ganchi PA. Postoperative monitoring of microvascular tissue transfers: Current practice in the United Kingdom and Ireland. *Plast Reconstr Surg* 2003;111:2118–2119.
  77. Creech B, Miller S. Evaluation of circulation in skin flaps. In: Grabb WC, Myers MB, editors. *Skin Flaps*. Boston: Little; 1975; 21–38.
  78. Jones BM. Monitors for the cutaneous microcirculation. *Plast Reconstr Surg* 1984;73:843–850.
  79. Scheufler O, Exner K, Andresen R. Investigation of TRAM flap oxygenation and perfusion by near-infrared reflection spectroscopy and color-coded duplex sonography. *Plast Reconstr Surg* 2004;113:141–152; discussion 53–55.
  80. Repez A, Oroszy D, Arnez ZM. Continuous postoperative monitoring of cutaneous free flaps using near infrared spectroscopy. *J Plast Reconstr Aesthet Surg* 2008;61:71–77.
  81. Mahoney JL, Lista FR. Variations in flap blood flow and tissue PO<sub>2</sub>: A new technique for monitoring flap viability. *Ann Plast Surg* 1988;20:43–47.
  82. Lindsey LA, Watson JD, Quaba AA. Pulse oximetry in postoperative monitoring of free muscle flaps. *Br J Plast Surg* 1991;44:27–29.
  83. Achauer BM, Black KS, Beran AV, Huxtable RF. Transcutaneous PO<sub>2</sub> monitoring of flap circulation following surgery. *Birth Defects Orig Artic Ser* 1979;15:517–522.
  84. Achauer BM, Black KS, Litke DK. Transcutaneous PO<sub>2</sub> in flaps: A new method of survival prediction. *Plast Reconstr Surg* 1980;65:738–745.
  85. Colwell AS, Wright L, Karanas Y. Near-infrared spectroscopy measures tissue oxygenation in free flaps for breast reconstruction. *Plast Reconstr Surg* 2008;121:344e–345e.
  86. Hashimoto I, Nakanishi H, Takiwaki H, Takase MT, Yamano M, Sedo H. Flap monitoring by transcutaneous PO<sub>2</sub> and PCO<sub>2</sub>: Importance of transcutaneous PCO<sub>2</sub> in determining follow-up treatment for compromised free flaps. *J Reconstr Microsurg* 2007;23:269–274.
  87. Hirigoyen MB, Blackwell KE, Zhang WX, Silver L, Weinberg H, Urken ML. Continuous tissue oxygen tension measurement as a monitor of free-flap viability. *Plast Reconstr Surg* 1997;99:763–773.
  88. Hjortdal VE, Awwad AM, Gottrup F, Kirkegaard L, Gellert S. Tissue oxygen tension measurement for monitoring musculocutaneous and cutaneous flaps. *Scand J Plast Reconstr Surg Hand Surg* 1990;24:27–30.
  89. Irwin MS, Thorniley MS, Dore CJ, Green CJ. Near infra-red spectroscopy: A non-invasive monitor of perfusion and oxygenation within the microcirculation of limbs and flaps. *Br J Plast Surg* 1995;48:14–22.
  90. Keller A. Noninvasive tissue oximetry for flap monitoring: an initial study. *J Reconstr Microsurg* 2007;23:189–197.
  91. Serafin D, Lesesne CB, Mullen RY, Georgiade NG. Transcutaneous PO<sub>2</sub> monitoring for assessing viability and predicting survival of skin flaps: Experimental and clinical correlations. *J Microsurg* 1981;2:165–178.
  92. Stack BC Jr, Futran ND, Zang B, Scharf JE. Initial experience with personal digital assistant-based reflectance photoplethysmograph for free tissue transfer monitoring. *Ann Plast Surg* 2003;51:136–140.
  93. Stack BC Jr, Futran ND, Shohet MJ, Scharf JE. Spectral analysis of photoplethysmograms from radial forearm free flaps. *Laryngoscope* 1998;108:1329–1333.
  94. Chiu ES, Altman A, Allen RJ Jr, Allen RJ Sr. Free flap monitoring using skin temperature strip indicators: Adjunct to clinical examination. *Plast Reconstr Surg* 2008;122:144e–145e.
  95. Issing WJ, Naumann C. Evaluation of pedicled skin flap viability by pH, temperature and fluorescein: An experimental study. *J Craniomaxillofac Surg* 1996;24:305–309.
  96. Silverman DG, Cedrone FA, Hurford WE, Bering TG, LaRossa DD. Monitoring tissue elimination of fluorescein with the perfusion fluorometer: A new method to assess capillary blood flow. *Surgery* 1981;90:409–417.
  97. Silverman DG, Groskopf RW, Ostrander LE, Lee BY, O'Connor TZ, Brousseau DA. Monitoring skin fluorescein delivery independent of skin pigmentation. *Surgery* 1990;108:48–55.
  98. Denny JC III, Weisman RA, Silverman DG. Monitoring free flap perfusion by serial fluorometry. *Otolaryngol Head Neck Surg* 1983;91:372–376.
  99. Eren S, Krein R, Hafemann B. Objective evaluation of the microcirculation in the skin with indocyanine green angiography (ICGA). A method for the clinic? *Handchir Mikrochir Plast Chir* 1995;27:307–314.
  100. Eren S, Rubben A, Krein R, Larkin G, Hettich R. Assessment of microcirculation of an axial skin flap using indocyanine green fluorescence angiography. *Plast Reconstr Surg* 1995;96:1636–1649.
  101. Silverman DG, Kim DJ, Brousseau DA, Kim M, Norton KJ, Reilly CA. Fluorescence assessment of skin perfusion after oral fluorescein. *Surgery* 1988;103:221–225.
  102. Whitney TM, Lineaweaver WC, Billys JB, Siko PP, Buncke GM, Alpert BS, Oliva A, Buncke HJ. Improved salvage of complicated microvascular transplants monitored with quantitative fluorometry. *Plast Reconstr Surg* 1992;90:105–111.
  103. Udesen A, Lontoft E, Kristensen SR. Monitoring of free TRAM flaps with microdialysis. *J Reconstr Microsurg* 2000;16:101–106.
  104. Mourouzis C, Anand R, Bowden JR, Brennan PA. Microdialysis: Use in the assessment of a buried bone-only fibular free flap. *Plast Reconstr Surg* 2007;120:1363–1366.
  105. Edsander-Nord A, Rojdmarm J, Wickman M. Metabolism in pedicled and free TRAM flaps: A comparison using the microdialysis technique. *Plast Reconstr Surg* 2002;109:664–673.
  106. Laure B, Sury F, Bayol JC, Goga D. Microdialysis: experience in postoperative monitoring of 30 free flaps. *Ann Chir Plast Esthet* 2009;54:29–36.
  107. Rosenberg JJ, Fornage BD, Chevray PM. Monitoring buried free flaps: Limitations of the implantable Doppler and use of color duplex sonography as a confirmatory test. *Plast Reconstr Surg* 2006;118:109–113; discussion 14–15.
  108. Prantl L, Pfister K, Kubale R, Schmitt S, Stockhammer V, Jung W, Zorger N, Herold T, Nerlich M, Stehr A, Jung EM. Value of high resolution ultrasound and contrast enhanced US pulse inversion imaging for the evaluation of the vascular integrity of free-flap grafts. *Clin Hemorheol Microcirc* 2007;36:203–216.
  109. Prantl L, Schmitt S, Geis S, Tsui TY, Lamby P, Nerlich M, Kubale R, Zorger N, Herold T, Feuerbach S, Jung EM. Contrast harmonic ultrasound and indocyanine-green fluorescence video angiography for evaluation of dermal and subdermal microcirculation in free parascapular flaps. *Clin Hemorheol Microcirc* 2008;38:105–118.
  110. Whitaker IS, Smit JM, Acosta R. A simple method of implantable Doppler cuff attachment: Experience in 150 DIEP breast reconstructions. *J Plast Reconstr Aesthet Surg* 2008;61:1251–1252.
  111. Swartz WM, Izquierdo R, Miller MJ. Implantable venous Doppler microvascular monitoring: Laboratory investigation and clinical results. *Plast Reconstr Surg* 1994;93:152–163.
  112. Solomon GA, Yaremchuk MJ, Manson PN. Doppler ultrasound surface monitoring of both arterial and venous flow in clinical free tissue transfers. *J Reconstr Microsurg* 1986;3:39–41.
  113. Smit J, Whitaker I, Liss A, Audolfsson T, Kildal M, Acosta R. Post operative monitoring of microvascular breast reconstructions using the implantable Cook-Swartz doppler system: A study of 145 probes and technical discussion. *J Plast Reconstr Aesthet Surg* 2009;62:1286–1292.
  114. Pryor SG, Moore EJ, Kasperbauer JL. Implantable Doppler flow system: Experience with 24 microvascular free-flap operations. *Otolaryngol Head Neck Surg* 2006;135:714–718.

115. de la Torre J, Hedden W, Grant JH III, Gardner PM, Fix RJ, Vasconez LO. Retrospective review of the internal Doppler probe for intra- and postoperative microvascular surveillance. *J Reconstr Microsurg* 2003;19:287–290.
116. Kind GM, Buntic RF, Buncke GM, Cooper TM, Siko PP, Buncke HJ Jr. The effect of an implantable Doppler probe on the salvage of microvascular tissue transplants. *Plast Reconstr Surg* 1998;101:1268–1273; discussion 74–75.
117. Oliver DW, Whitaker IS, Giele H, Critchley P, Cassell O. The Cook-Swartz venous Doppler probe for the post-operative monitoring of free tissue transfers in the United Kingdom: A preliminary report. *Br J Plast Surg* 2005;58:366–370.
118. Parker PM, Fischer JC, Shaw WW. Implantable pulsed Doppler cuff for long-term monitoring of free flaps: A preliminary study. *Microsurgery* 1984;5:130–135.
119. Swartz WM, Jones NF, Cherup L, Klein A. Direct monitoring of microvascular anastomoses with the 20-MHz ultrasonic Doppler probe: An experimental and clinical study. *Plast Reconstr Surg* 1988;81:149–161.
120. Yuen JC, Feng Z. Monitoring free flaps using the laser Doppler flowmeter: Five-year experience. *Plast Reconstr Surg* 2000;105:55–61.
121. Svensson H, Pettersson H, Svedman P. Laser Doppler flowmetry and laser photometry for monitoring free flaps. *Scand J Plast Reconstr Surg* 1985;19:245–249.
122. Hallock GG, Koch TJ. External monitoring of vascularized jejunum transfers using laser Doppler flowmetry. *Ann Plast Surg* 1990;24:213–215.
123. Hölzle F, Loeffelbein DJ, Nolte D, Wolff K-D. Free flap monitoring using simultaneous non-invasive laser Doppler flowmetry and tissue spectrophotometry. *J Craniomaxillofac Surg* 2006;34:25–33.
124. Knobloch K, Gohritz A, Vogt PM. Noninvasive monitoring of microcirculatory perfusion and oxygenation in subcutaneous microsurgical flaps. *J Reconstr Microsurg* 2008;24:69.
125. Liss AG, Liss P. Use of a modified oxygen microelectrode and laser-Doppler flowmetry to monitor changes in oxygen tension and microcirculation in a flap. *Plast Reconstr Surg* 2000;105:2072–2078.
126. Goldberg J, Sepka RS, Perona BP, Pederson WC, Klitzman B. Laser Doppler blood flow measurements of common cutaneous donor sites for reconstructive surgery. *Plast Reconstr Surg* 1990;85:581–586.
127. Concannon MJ, Stewart DH, Welsh CF, Puckett CL. Impedance plethysmography: A new method for continuous muscle perfusion monitoring. *Plast Reconstr Surg* 1991;88:292–298.
128. Harrison DH, Mott G. Impedance monitoring for subcutaneous free flap transfers. *Br J Plast Surg* 1989;42:318–323.
129. Larsson L. An electrophysiological method for monitoring blood flow in skeletal muscle. An experimental study in the rat. *Scand J Plast Reconstr Surg Hand Surg* 1989;23:181–186.
130. Altintas MA, Altintas AA, Guggenheim M, Knobloch K, Niederbichler AD, Vogt PM. Monitoring of microcirculation in free transferred musculocutaneous latissimus dorsi flaps by confocal laser scanning microscopy—A promising non-invasive methodical approach. *J Plast Reconstr Aesthet Surg* 2010;63:111–117.
131. Top H, Sarikaya A, Aygit AC, Benlier E, Kiyak M. Review of monitoring free muscle flap transfers in reconstructive surgery: Role of 99mTc sestamibi scintigraphy. *Nucl Med Commun* 2006;27:91–98.
132. Aygit AC, Sarikaya A. Technetium 99m sestamibi scintigraphy for noninvasive assessment of muscle flap viability. *Ann Plast Surg* 1999;43:338–340.
133. Tsuchida Y. Age-related changes in skin blood flow at four anatomic sites of the body in males studied by xenon-133. *Plast Reconstr Surg* 1990;85:556–561.
134. Raskin DJ, Erk Y, Spira M, Melissinos EG. Tissue pH monitoring in microsurgery: A preliminary evaluation of continuous tissue pH monitoring as an indicator of perfusion disturbances in microvascular free flaps. *Ann Plast Surg* 1983;11:331–339.
135. Dickson MG, Sharpe DT. Continuous subcutaneous tissue pH measurement as a monitor of blood flow in skin flaps: An experimental study. *Br J Plast Surg* 1985;38:39–42.
136. Dunn RM, Kaplan IB, Mancoll J, Terzis JK, Trengove-Jones G. Experimental and clinical use of pH monitoring of free tissue transfers. *Ann Plast Surg* 1993;31:539–545.
137. Machens HG, Mailaender P, Reimer R, Pallua N, Lei Y, Berger A. Postoperative blood flow monitoring after free-tissue transfer by means of the hydrogen clearance technique. *Plast Reconstr Surg* 1997;99:493–505.
138. Thomson JG, Kerrigan CL. Hydrogen clearance: Assessment of technique for measurement of skin-flap blood flow in pigs. *Plast Reconstr Surg* 1991;88:657–663.
139. Yang JC, Kuo YR, Hsieh CH, Jeng SF. The use of radial vessel stump in free radial forearm flap as flap monitor in head and neck reconstruction. *Ann Plast Surg* 2007;59:378–381.
140. Rozen WM, Chubb D, Whitaker IS, Acosta R. The efficacy of postoperative monitoring: A single surgeon comparison of clinical monitoring and the implantable Doppler probe in 547 consecutive free flaps. *Microsurgery* 2010;30:105–110.
141. Langer S, Biberthaler P, Harris AG, Steinau HU, Messmer K. In vivo monitoring of microvessels in skin flaps: Introduction of a novel technique. *Microsurgery* 2001;21:317–324.
142. Briers JD. Laser Doppler, speckle and related techniques for blood perfusion mapping and imaging. *Physiol Meas* 2001;22:R35–R66.
143. Erdmann D, Sweis R, Wong MS, Eyler CE, Olbrich KC, Levin LS, Germann G, Klitzman B. Current perspectives of orthogonal polarization spectral imaging in plastic surgery. *Chirurg* 2002;73:827–832.
144. Olivier W-AM, Hazen A, Levine JP, Soltanian H, Chung S, Gurtner GC. Reliable assessment of skin flap viability using orthogonal polarization imaging. *Plast Reconstr Surg* 2003;112:547–555.
145. Rozen WM, Garcia-Tutor E, Alonso-Burgos A, Acosta R, Stillaert F, Zubieta J, Hamdi M, Whitaker IS, Ashton MW. Planning and optimising DIEP flaps with virtual surgery: The Navarra experience. *J Plast Reconstr Aesthet Surg* 2010;63:289–297.